

Potential of Honey in the Treatment of Wounds and Burns

Peter C. Molan

Honey Research Unit, University of Waikato, Hamilton, New Zealand

Contents

Abstract	13
1. Background	13
2. The Effectiveness of Honey in Wound Treatment	13
3. How Honey Works on Wounds	15
4. Using Honey in Clinical Practice	17
5. Conclusion	18

Abstract

There has been a renaissance in recent times in the use of honey, an ancient and traditional wound dressing, for the treatment of wounds, burns, and skin ulcers. In the past decade there have been many reports of case studies, experiments using animal models, and randomized controlled clinical trials that provide a large body of very convincing evidence for its effectiveness, and biomedical research that explains how honey produces such good results.

As a dressing on wounds, honey provides a moist healing environment, rapidly clears infection, deodorizes, and reduces inflammation, edema, and exudation. Also, it increases the rate of healing by stimulation of angiogenesis, granulation, and epithelialization, making skin grafting unnecessary and giving excellent cosmetic results.

1. Background

In 1989, an editorial in the *Journal of the Royal Society of Medicine*^[1] noted the renaissance of the use of honey in wound treatment, and expressed the opinion that ‘The time has now come for conventional medicine to lift the blinds off this ‘traditional remedy’ and give it its due recognition.’ Honey is the most ancient wound dressing known,^[2,3] and it has continued to be used throughout the ages. Dioscorides^[4] (c.50 AD) wrote of honey being ‘good for sunburn’ and ‘for all rotten and hollow ulcers’, and its usage has continued into present-day folk-medicine. It is used as a traditional therapy in Ghana for infected leg ulcers,^[5] and in Mali for the topical treatment of measles and to prevent corneal scarring from measles.^[6]

Although there is an increasing interest in ‘alternative medicine’, particularly as a result of the mounting problem of anti-bacterial resistance in bacteria, there is a tendency in modern medicine for traditional treatments to be dismissed without due consideration. An editorial in *Archives of Internal Medicine* as-

signed honey to the category of ‘worthless but harmless substances’.^[7] Other editorials have shown a lack of awareness of the research that has demonstrated the rational explanations for the therapeutic effects of honey.^[8,9] This article has been written to bring to attention the many reports of case studies, experiments on animal models, randomized controlled clinical trials, and laboratory research that provide a large body of very convincing evidence for the effectiveness of honey in the treatment of wounds, ulcers, and burns. This article also outlines how honey can be used to good effect in clinical practice.

2. The Effectiveness of Honey in Wound Treatment

There are many reports in the clinical literature of honey being used with success in the treatment of a wide range of wounds: the types of wound are shown in table I. Commonly reported features observed when honey is used are the rapid clearance of bacteria from colonized and infected wounds,^[10-13,15-18,21,31,37] the rapid removal of malodour from wounds,^[11,13,21,23,24,31,32] and the de-

Table I. Types of wounds on which honey has been used successfully

Infected wounds arising from trauma ^[10-14] and surgery, ^[11,12,15-19] including: amputation wounds ^[20] vulvectomy wounds ^[11,16,17,19] burst abdominal wounds following Cesarean delivery ^[21] donor sites from split-thickness skin grafting ^[22]
Burns ^[12,13,23-30]
Skin lesions from meningococcal septicemia ^[22]
Fournier's gangrene ^[13,31,32]
Pressure sores ^[13,20,27,33]
Skin ulcers ^[13,27,34] including: leg ulcers ^[14,35] varicose ulcers ^[14,17,36] diabetic ulcers ^[13,14,34] tropical ulcers ^[13] foot ulcers in patients with leprosy ^[34] sickle cell ulcers ^[13] malignant ulcers ^[13]

bridging effect, which painlessly lifts off slough and necrotic tissue, making surgical debridement unnecessary.^[13,17,20,23-25,31,32] Other notable features of honey that have been reported are the rapid rate of healing achieved^[19,26,27,32] and its ability to start the healing process in recalcitrant chronic wounds.^[12-14,20,33,35,36] It has been observed that honey promotes tissue regeneration through stimulation of angiogenesis and the growth of fibroblasts and epithelial cells,^[13,28,29,31,32] thereby hastening healing and minimizing the need for skin grafting.^[11,16,28,31,32]

The evidence for the effectiveness of honey in wound treatment has been reviewed in detail elsewhere.^[38] It consists of case reports, studies of experimental wounds in animal models, and randomized controlled clinical trials.

There are numerous case reports where wounds that had not been responding to conventional treatment healed when treatment was changed to dressing with honey.^[12-15,20,33,36] One of these reports^[15] was of 9 infants who had large infected surgical wounds still open and oozing pus after treatment for at least 14 days with intravenous antibacterials and wound cleansing with aqueous chlorhexidine solution (0.05% w/v) and fusidic acid ointment. Marked clinical improvement was seen in all infants after 5 days of dressing with honey, and the wounds were closed, clean, and sterile in all of the infants after 21 days of honey application.

The studies in animal models have demonstrated that honey gives faster healing and reduced inflammation (from histologic evidence), compared with various controls, in superficial burns^[26] and in full-thickness wounds free from infection^[19,39,40] and wounds experimentally infected with *Staphylococcus aureus*.^[41] These

effects have been shown to be due to components other than the sugar in honey.^[26]

Prospective, randomized, controlled, clinical trials have proven that honey gives significantly ($p < 0.001$) more rapid healing of superficial burns than the healing achieved with silver sulfadiazine,^[23,28] a polyurethane film,^[24] and amniotic membrane.^[29]

In one of the trials comparing honey and silver sulfadiazine,^[23] in the 52 patients treated with honey 91% of the wounds were rendered sterile within 7 days but in the 52 patients treated with silver sulfadiazine only 7% showed control of infection within 7 days. Healthy granulation tissue was observed earlier in patients treated with honey than those treated with silver sulfadiazine (means 7.4 versus 13.4 days). Of those dressed with honey 87% of wounds had healed within 15 days compared with 10% of those treated with silver sulfadiazine. Better relief of pain, less exudation, less irritation of the wound, and a lower incidence of hypertrophic scar and post-burn contracture were noted with the honey treatment. In the other trial comparing honey with silver sulfadiazine,^[28] histologic examination of biopsy samples from the wound margin as well as clinical observations of wound healing were made to assess relative effects on wound healing in the 2 groups of 25 patients. By the 7th day, 84% of the wounds dressed with honey showed satisfactory epithelialization, compared with 72% of those dressed with silver sulfadiazine, and by the 21st day this had increased to 100% of the wounds dressed with honey compared with 84% of the wounds dressed with silver sulfadiazine. Histologic evidence of reparative activity showed similar differences between the 2 groups, and showed early subsidence of acute inflammatory changes in the honey-dressed wounds, whereas a sustained inflammatory reaction was seen even on epithelialization in the wounds treated with silver sulfadiazine. No skin grafting was required for the wounds treated with honey, but 4 of the wounds treated with silver sulfadiazine converted to full thickness and required skin grafts.

In a trial comparing honey-impregnated gauze with a polyurethane film (OpSite[®]), in 2 groups of 46 patients,^[24] the wounds dressed with honey healed in a mean time of 10.8 days compared with 15.3 days with the polyurethane film. Less than half as many of the wounds became infected when the wounds were dressed with honey compared with when the wounds were dressed with the polyurethane film ($p < 0.001$).

In a trial comparing honey-impregnated gauze with amniotic membrane,^[29] the 40 patients treated with honey-impregnated gauze had their burns healed in a mean time of 9.4 days compared with 17.5 days for the 24 patients treated with amniotic membrane. Residual scars were noted in 8% of patients treated with honey-impregnated gauze and in 16.6% of cases treated with amniotic membrane ($p < 0.001$).

A retrospective study of 156 burn patients treated in a hospital over a period of 5 years (1988 to 1992)^[30] found that the 13 patients treated with honey had a similar outcome to those treated with silver sulfadiazine. However, in a prospective, randomized, controlled trial on deep burns it was found that honey dressing was not as good as early tangential excision and skin grafting.^[42]

Other clinical trials^[21,31] have investigated the treatment of wounds with honey and the results have then been compared retrospectively with the results from control groups whose wounds were treated conventionally. In one trial,^[31] 20 consecutive patients with Fournier's gangrene were managed conservatively with honey dressings in addition to systemic antibacterials (to which some of the bacteria isolated were subsequently found not to be sensitive). The results from these patients were compared retrospectively with the results from 21 similar patients managed by the orthodox method of wound debridement, wound excision, secondary suturing, and in some cases scrotal plastic reconstruction, in addition to receiving a mixture of systemic antibacterials (as dictated by sensitivity results from cultures). The average duration of hospitalization was slightly longer, but response to treatment and alleviation of morbidity were faster in the group treated with honey.

The second trial^[21] was a prospective trial conducted over 2 years involving 15 women with wound dehiscence following Cesarean section. They had their abdominal wound disruption managed by honey dressing and wound approximation by micropore tape. The results of this trial were then compared retrospectively with 19 patients of a similar age who had undergone Cesarean section over the preceding 2 years and who had had their dehisced wounds cleaned with hydrogen peroxide and hypochlorite solution and packed with saline-soaked gauze prior to resuturing under general anesthesia. Excellent results were achieved in all the patients treated with honey, the period of hospitalization required being 2 to 7 days (mean 4.5), compared with 9 to 18 days (mean 11.5) for the comparative group.

3. How Honey Works on Wounds

The composition of honey is outlined in table II. It provides a moist environment for optimum healing conditions despite its water activity (amount of 'free' water) being very low. It does not cause dehydration of tissues because its osmotic effect draws fluid through the wound tissue from the underlying circulation.^[47] Thus it creates a film of diluted honey under the dressing, which prevents the dressing from adhering to the wound bed so there is no tearing away of newly formed tissue, and no pain, on changing dressings.^[11,17,24,32] A bonus from the osmotic effect that creates this moist healing environment is that it provides

oxygenation and nutrification for the traumatized tissue through the flow of lymph that is induced. Additional nutrification is provided by components of honey. Topical application of nutrients to wounds has been shown to increase the rate of growth of granulation tissue.^[48] Within this moist environment the high osmolarity of honey protects skin from maceration, and the antibacterial activity of honey prevents bacterial growth. As a viscous fluid it also provides a protective barrier to prevent cross-infection of wounds.^[11,13,19,23,24]

Many authors are not aware that honey has an antibacterial activity beyond the osmotic effect of its sugar content,^[9,10,33,34,49-51] yet there have been numerous microbiologic studies published that have shown that in many honeys there are other components present that give a much more potent antibacterial effect than that due to the osmolarity.^[45] Although the major antibacterial agent in honey, hydrogen peroxide, has generally gone out of use in wound care because of its inflammatory effects, the concentration of hydrogen peroxide accumulating in a honey dressing (typically around 1 mmol/L is produced in honey^[52]) would be about 1000 times less than that in a 3% solution of hydrogen peroxide. Honey can be a potent antibacterial agent: testing of honeys of median levels of activity has shown that even when diluted 10 times or more they are capable of complete inhibition of the common species of wound-infecting bacteria,^[53] with little variation in the sensitivity of a range of clinical isolates of *S. aureus*^[54] and *Pseudomonas*.^[55]

Another way that honey may work in clearing infection is through an activating effect on the body's immune system, as it has been reported that it stimulates mitogenesis in B and T lymphocytes and activates neutrophils.^[56] It also provides a plentiful

Table II. Components and features of honey that are relevant to wound healing

Comprises a viscous saturated or supersaturated solution of sugars
Typically contains about 20% water (almost all bound up with the sugar molecules)
Sugars: primarily glucose and fructose
Wide range of amino acids, vitamins, and minerals ^[43]
Antioxidants ^[44]
Glucose oxidase which produces hydrogen peroxide and gluconic acid ^[43]
Gluconic acid gives honey a pH typically of 3.2 to 4.5 ^[43]
Hydrogen peroxide is produced only when honey is diluted as glucose oxidase is inhibited in undiluted honey ^[45]
Hydrogen peroxide provides most of the antibacterial activity of diluted honey (in undiluted honey the high osmolarity prevents bacterial growth) ^[45]
Antibacterial phytochemicals may also be present [honey from manuka (<i>Leptospermum scoparium</i>) has a high level of such phytochemicals] ^[46]

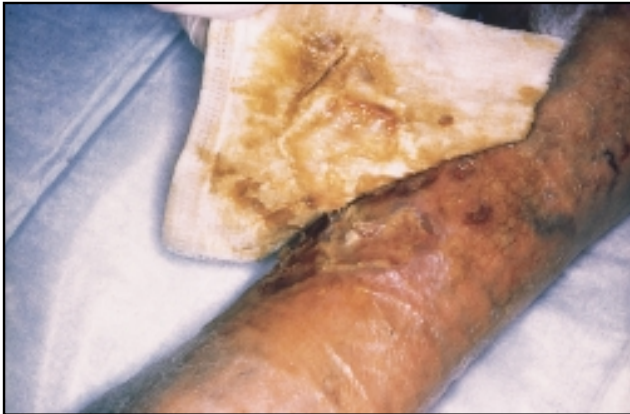

Fig. 1. The debriding action of honey detaches slough so that it lifts off with the dressing.

supply of glucose which is essential for the 'respiratory burst' of phagocytes.

The rapid autolytic debridement of wounds seen when honey is used (fig. 1) may result from the activation of proteases in the wound tissue by the hydrogen peroxide produced by honey: the matrix metalloprotease is activated by oxidation,^[57] and the inhibitor of neutrophil protease in wound tissue is inactivated by oxidation.^[58]

The anti-inflammatory action of honey observed clinically as a reduction in edema^[13,25,31] and pain^[24,26,50] is not just a secondary effect of clearing infection and debriding the wound, as it has been observed also in experimental wounds in animal models

in which there were few or no bacteria.^[26,40] By decreasing edema honey improves the circulation through capillaries and thus improves oxygenation, the rate-limiting factor for regenerating tissues in the wound. The acidity of honey also helps with oxygenation, as acidification of wounds increases the release of oxygen from hemoglobin.^[59]

The anti-inflammatory action of honey will also reduce the damage that is caused by the free radicals that arise from inflammation, thus preventing further necrosis.^[60] For example, it has been observed that honey prevents partial-thickness burns from converting to full-thickness burns needing skin grafts.^[28] The antioxidants present in honey will help in this, by 'mopping up' any free radicals that are formed. Topical application of antioxidants has been found to reduce the ischaemia associated with burns.^[61] These effects will reduce the level of reactive oxygen species, the prolonged production of which is responsible for the occurrence of fibrosis.^[62]

The stimulation of angiogenesis that has been observed experimentally when honey is applied to wounds in animal models^[39,41] would account for the notably rapid development of granulation tissue seen clinically,^[13,16,18,20,23,28,31,35] as the granules are fibroblasts growing where there are capillary bundles supplying oxygen. There is currently no explanation for how honey stimulates angiogenesis, although it could be through its production of hydrogen peroxide, as topical application of hydrogen peroxide has been found to enhance cutaneous blood recruitment in ischaemic ulcers.^[63] It may also be through the production of hydrogen peroxide that honey promotes the rapid healing of wounds, as hydro-

Table III. Some practical considerations using honey in clinical practice

The various beneficial effects of honey on wound tissues will be reduced or lost if small amounts of honey become diluted by large amounts of exudate
The frequency of dressing changes required depends on how rapidly the honey is being diluted by exudate
More honey is required on deeper infections, to obtain an effective level of antibacterial activity diffusing deep into the wound tissues
Typically, 20ml of honey (25 to 30g) is used on a 10cm x 10cm absorbent dressing pad
Most commonly, dressing are changed daily, but up to 3 times daily may be needed at first for heavily exuding wounds
The antibacterial and anti-inflammatory action of honey soon reduces the amount of exudation from the wound – twice-weekly dressing changes may be suitable later
A heavy flow of exudate tends to wash the honey to the outer surface of the dressing, thus allowing the dressing to stick to the wound: more frequent dressing changes prevent this
If a non-adherent dressing is used under the honey dressing, it has to have sufficient porosity to allow the components of the honey to diffuse through to the wound bed (paraffin-impregnated dressings prevent diffusion from the honey)
Honey at body temperature is fluid and tends to run off wounds (fig. 2). Absorbent dressing pads preimpregnated with honey are the most convenient way of applying honey to surface wounds (fig. 3)
Filling abscesses, cavities and depressions in the wound bed with honey before applying the honey dressing pad ensures honey is always in contact with the wound bed (fig. 4)
Occlusive or absorbent secondary dressings are needed to prevent honey oozing out from the wound dressing. Occlusive dressings have the advantage of preventing honey from soaking away from the wound (the high osmolarity of honey prevents maceration of the skin)
Where there is no problem with containing exudate, fluid honey can be held in place on a wound by an adhesive polyurethane film dressing
For varicose ulcers, multi-layer pressure bandaging can be used over honey-impregnated dressing pads

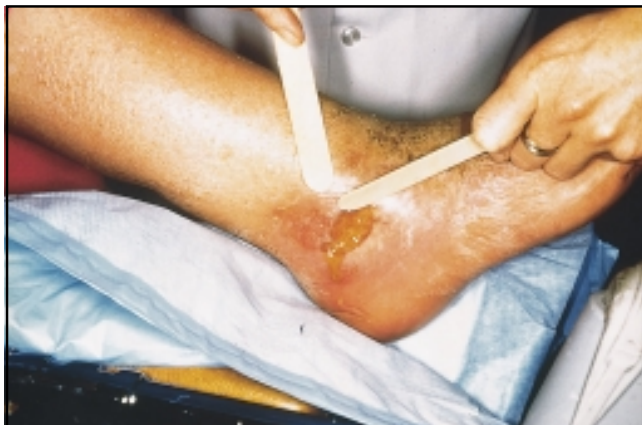

Fig. 2. Honey applied directly to surface wounds tends to run off.

gen peroxide has been found to stimulate the proliferation of fibroblasts.^[64] It has been proposed that hydrogen peroxide could be used to promote the wound healing process if the concentration could be carefully controlled:^[64] controlled sustained release of hydrogen peroxide is achieved with honey. It has also been proposed that honey be used in place of recombinant growth factors to stimulate the healing of burns.^[65]

4. Using Honey in Clinical Practice

The published literature on the clinical usage of honey in wound care gives little detail on the way that wounds are dressed with honey, and that which is given varies. Table III outlines

some practical considerations that come from clinical associates experienced in the use of honey as a wound dressing.

Another consideration is the selection of honey for use as a wound dressing. Two millennia ago physicians were aware that only certain honeys should be used for therapeutic purposes,^[4,66] but in present times honey is mostly treated as a generic medicine. Because the antibacterial activity of different honeys can vary by as much as 100-fold,^[52] the best results on infected wounds would be expected if the honey used were selected to have a high level of activity. Honey to be used on wounds should be protected from heat and light because the antibacterial activity of honey is easily lost through the denaturing action of these on the enzyme in honey that produces hydrogen peroxide.^[52]

Because honey sometimes contains viable spores of *Clostridium botulinum* it has been argued that the risk of it possibly causing wound botulism is unacceptable.^[51] Honey is too viscous for filter-sterilization, and its antibacterial activity is destroyed by heating, but honey can be sterilized by gamma-irradiation^[67,68] without loss of activity.^[67] Pure *Leptospermum* honey with standardized antibacterial activity, packed in squeeze-out tubes for ease of use, sterilized by gamma-irradiation, is available commercially in Australia and New Zealand from various producers.

For follow-up protection of delicate new skin after completion of epithelialization, honey can be applied by being incorporated in skin creams or ointments.^[22] These are commercially available in New Zealand, consisting of normal moisturising creams or a petrolatum-based ointment with 25 to 30% manuka honey with standardized antibacterial activity incorporated. With sufficient lipid material in the formulation, these can contain a high proportion of honey without it being sticky on the skin.

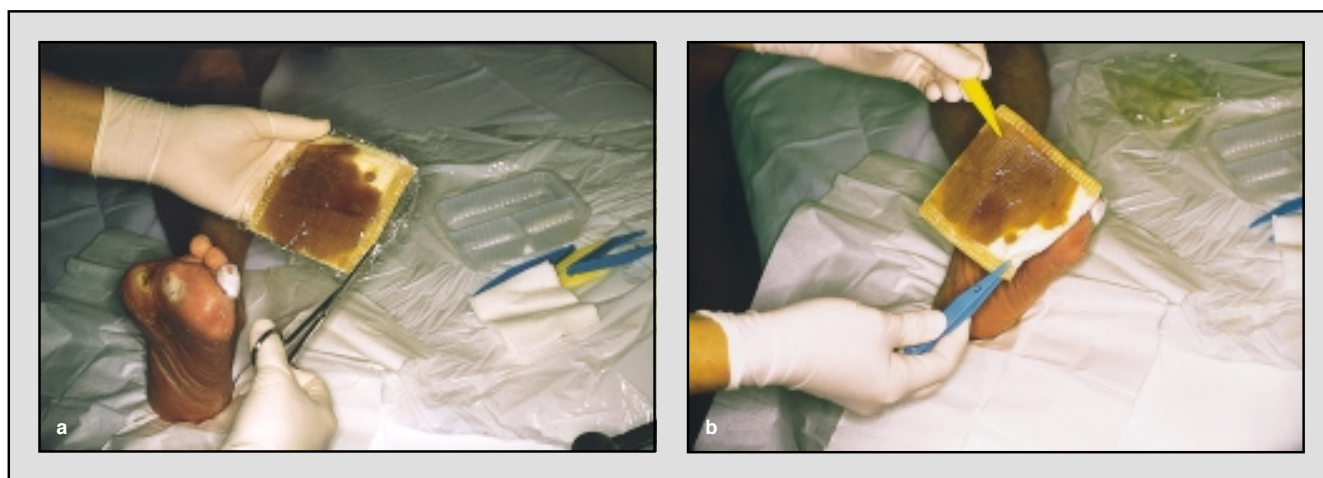


Fig. 3. Absorbent dressings pre-impregnated with honey are a convenient way of applying honey to a wound, and of holding an appropriate quantity of honey in place.

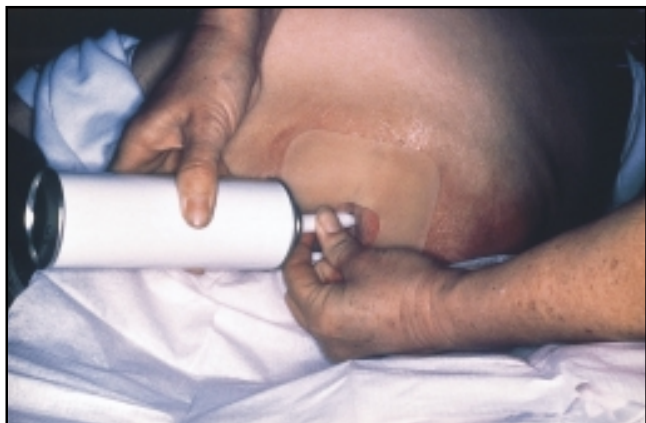

Fig. 4. A pressurized system being used to fill a sinus with sterilized honey.

5. Conclusion

Honey is the most ancient wound dressing known, but as a bioactive dressing material it is also the most modern type of wound dressing. Apart from the difficulty of keeping honey in place on a wound and absorbing exudate, it meets all of the criteria for being the perfect dressing material. With appropriate dressing techniques, those shortcomings can be overcome. Honey selected to have a good antibacterial activity provides a treatment option worthy of serious consideration, especially on infected and recalcitrant wounds. On burns its antibacterial and anti-inflammatory properties allow a moist healing environment to be maintained that protects the wounds from deterioration and fibrosis. Its promotion of rapid healing and minimization of scarring also warrant it having a place in plastic surgery.

Acknowledgements

The advice of Julie Betts, Wound Resource Nurse, Community Health, Health Waikato Ltd., New Zealand, and Val Robson, Clinical Nurse Specialist Leg Ulcer Care, University Hospital Aintree, Liverpool, England, on the practical aspects of the clinical usage of honey is gratefully acknowledged. Photographs were provided by Julie Betts.

References

- Zumla A, Lulat A. Honey – a remedy rediscovered. *J R Soc Med* 1989; 82: 384-5
- Majno G. *The healing hand. Man and wound in the ancient world.* Cambridge (MA): Harvard University Press, 1975
- Forrest RD. Early history of wound treatment. *J R Soc Med* 1982; 75: 198-205
- Gunther RT. *The Greek herbal of Dioscorides.* New York: Hafner, 1934. Reprinted 1959
- Ankra-Badu GA. Sick cell leg ulcers in Ghana. *East Afr Med J* 1992; 69 (7): 366-9
- Imperato PJ, Traoré D. Traditional beliefs about measles and its treatment among the Bambara of Mali. *Trop Geogr Med* 1969; 21: 62-7
- Soffer A. Chihuahuas and laetrile, chelation therapy, and honey from Boulder, Colorado [editorial]. *Arch Intern Med* 1976; 136: 865-6
- Honey: sweet and dangerous or panacea [editorial]? *S Afr Med J* 1974; 56: 2300
- Condon RE. Curious interaction of bugs and bees [editorial]. *Surgery* 1993; 113 (2): 234-5
- Green AE. Wound healing properties of honey. *Br J Surg* 1988; 75 (12): 1278
- McInerney RJF. Honey – a remedy rediscovered. *J R Soc Med* 1990; 83: 127
- Ndayisaba G, Bazira L, Habonimana E, et al. Clinical and bacteriological results in wounds treated with honey. *J Orthop Surg* 1993; 7 (2): 202-4
- Efem SEE. Clinical observations on the wound healing properties of honey. *Br J Surg* 1988; 75: 679-81
- Wood B, Rademaker M, Molan PC. Manuka honey, a low cost leg ulcer dressing. *N Z Med J* 1997; 110: 107
- Vardi A, Barzilay Z, Linder N, et al. Local application of honey for treatment of neonatal postoperative wound infection. *Acta Paediatr* 1998; 87 (4): 429-32
- Cavanagh D, Beazley J, Ostapowicz F. Radical operation for carcinoma of the vulva. A new approach to wound healing. *J Obstet Gynaecol Br Commonw* 1970; 77 (11): 1037-40
- Bulman MW. Honey as a surgical dressing. *Middlesex Hosp J* 1955; 55: 188-9
- Armon PJ. The use of honey in the treatment of infected wounds. *Trop Doct* 1980; 10: 91
- Bergman A, Yanai J, Weiss J, et al. Acceleration of wound healing by topical application of honey. An animal model. *Am J Surg* 1983; 145: 374-6
- Hutton DJ. Treatment of pressure sores. *Nurs Times* 1966; 62 (46): 1533-4
- Phuapradit W, Saropala N. Topical application of honey in treatment of abdominal wound disruption. *Aust N Z J Obstet Gynaecol* 1992; 32 (4): 381-4
- Dunford C, Cooper RA, Molan PC. Using honey as a dressing for infected skin lesions. *Nurs Times* 2000; 96 (NTPLUS 14): 7-9
- Subrahmanyam M. Topical application of honey in treatment of burns. *Br J Surg* 1991; 78 (4): 497-8
- Subrahmanyam M. Honey impregnated gauze versus polyurethane film (OpSite®) in the treatment of burns – a prospective randomised study. *Br J Plast Surg* 1993; 46 (4): 322-3
- Subrahmanyam M. Honey dressing versus boiled potato peel in the treatment of burns: a prospective randomized study. *Burns* 1996; 22 (6): 491-3
- Burlando F. Sull'azione terapeutica del miele nelle ustioni. *Minerva Dermatol* 1978; 113: 699-706
- Blomfield R. Honey for decubitus ulcers. *J Am Med Assoc* 1973; 224 (6): 905
- Subrahmanyam M. A prospective randomised clinical and histological study of superficial burn wound healing with honey and silver sulfadiazine. *Burns* 1998; 24 (2): 157-61
- Subrahmanyam M. Honey-impregnated gauze versus amniotic membrane in the treatment of burns. *Burns* 1994; 20 (4): 331-3
- Adesunkanmi K, Oyelami OA. The pattern and outcome of burn injuries at Wesley Guild Hospital, Ilesha, Nigeria: a review of 156 cases. *J Trop Med Hyg* 1994; 97 (2): 108-12
- Efem SEE. Recent advances in the management of Fournier's gangrene: preliminary observations. *Surgery* 1993; 113 (2): 200-4
- Hejase MJ, E, SJ, Bihrl R, et al. Genital Fournier's gangrene: experience with 38 patients. *Urology* 1996; 47 (5): 734-9
- Somerfield SD. Honey and healing. *J R Soc Med* 1991; 84 (3): 179
- Tovey FI. Honey and healing. *J R Soc Med* 1991; 84 (7): 447
- Harris S. Honey for the treatment of superficial wounds: a case report and review. *Primary Intention (Aust J Wound Manage)* 1994; 2 (4): 18-23
- Bloomfield E. Old remedies. *J R Coll Gen Pract* 1976; 26: 576
- Braniki FJ. Surgery in Western Kenya. *Ann R Coll Surg Engl* 1981; 63: 348-52
- Molan PC. A brief review of honey as a clinical dressing. *Primary Intention (Aust J Wound Manage)* 1998; 6 (4): 148-58
- Kumar A, Sharma VK, Singh HP, et al. Efficacy of some indigenous drugs in tissue repair in buffaloes. *Indian Vet J* 1993; 70 (1): 42-4
- Oryan A, Zaker SR. Effects of topical application of honey on cutaneous wound healing in rabbits. *J Vet Med Ser A* 1998; 45 (3): 181-8

41. Gupta SK, Singh H, Varshney AC, et al. Therapeutic efficacy of honey in infected wounds in buffaloes. *Indian J Anim Sci* 1992; 62 (6): 521-3
42. Subrahmanyam M. Early tangential excision and skin grafting of moderate burns is superior to honey dressing: a prospective randomised trial. *Burns* 1999; 25 (8): 729-31
43. White JW. Composition of honey. In: Crane E, editor. *Honey: a comprehensive survey*. London: Heinemann, 1975: 157-206
44. Frankel S, Robinson GE, Berenbaum MR. Antioxidant capacity and correlated characteristics of 14 unifloral honeys. *J Apic Res* 1998; 37 (1): 27-31
45. Molan PC. The antibacterial activity of honey. 1. The nature of the antibacterial activity. *Bee World* 1992; 73 (1): 5-28
46. Allen KL, Molan PC, Reid GM. A survey of the antibacterial activity of some New Zealand honeys. *J Pharm Pharmacol* 1991; 43 (12): 817-22
47. Chirife J, Herszage L, Joseph A, et al. In vitro study of bacterial growth inhibition in concentrated sugar solutions: microbiological basis for the use of sugar in treating infected wounds. *Antimicrob Agents Chemother* 1983; 23 (5): 766-73
48. Kaufman T, Levin M, Hurwitz DJ. The effect of topical hyperalimination on wound healing rate and granulation tissue formation of experimental deep second degree burns in guinea-pigs. *Burns* 1984; 10 (4): 252-6
49. Bose B. Honey or sugar in treatment of infected wounds? *Lancet* 1982 Apr; I (24): 963
50. Keast-Butler J. Honey for necrotic malignant breast ulcers. *Lancet* 1980 Oct; II (11): 809
51. Mossel DAA. Honey for necrotic breast ulcers. *Lancet* 1980 Nov; II (15): 1091
52. Molan PC. The antibacterial activity of honey. 2. Variation in the potency of the antibacterial activity. *Bee World* 1992; 73 (2): 59-76
53. Willix DJ, Molan PC, Harfoot CJ. A comparison of the sensitivity of wound-infecting species of bacteria to the antibacterial activity of manuka honey and other honey. *J Appl Bacteriol* 1992; 73: 388-94
54. Cooper RA, Molan PC, Harding KG. Antibacterial activity of honey against strains of *Staphylococcus aureus* from infected wounds. *J R Soc Med* 1999; 92: 283-5
55. Cooper RA, Molan PC. The use of honey as an antiseptic in managing *Pseudomonas* infection. *J Wound Care* 1999; 8 (4): 161-4
56. Abuharfeil N, Al-Oran R, Abo-Shehada M. The effect of bee honey on the proliferative activity of human B- and T-lymphocytes and the activity of phagocytes. *Food Agric Immunol* 1999; 11: 169-77
57. Van Wart HE, Birkedal-Hansen H. The cystein switch: a principle of regulation of metalloproteinase activity with potential applicability to the entire matrix metalloproteinase gene family. *Proc Nat Acad Sci U S A* 1990; 87 (14): 5578-82
58. Flohé L, Beckmann R, Giertz H, et al. Oxygen-centred free radicals as mediators of inflammation. In: Sies H, editor. *Oxidative stress*. London, Orlando: Academic Press, 1985: 403-35
59. Kaufman T, Eichenlaub EH, Angel MF, et al. Topical acidification promotes healing of experimental deep partial thickness skin burns: a randomised double-blind preliminary study. *Burns* 1985; 12: 84-90
60. Kaufman T, Neuman RA, Weinberg A. Is postburn dermal ischaemia enhanced by oxygen free radicals? *Burns* 1989; 15 (5): 291-4
61. Tanaka H, Hanumadass M, Matsuda H, et al. Hemodynamic effects of delayed initiation of antioxidant therapy (beginning two hours after burn) in extensive third-degree burns. *J Burn Care Rehabil* 1995; 16 (6): 610-5
62. Murrell GAC, Francis MJO, Bromley L. Modulation of fibroblast proliferation by oxygen free radicals. *Biochem J* 1990; 265: 659-65
63. Tur E, Bolton L, Constantine BE. Topical hydrogen peroxide treatment of ischemic ulcers in the guinea pig: blood recruitment in multiple skin sites. *J Am Acad Dermatol* 1995; 33 (2 Pt 1): 217-21
64. Chung LY, Schmidt RJ, Andrews AM, et al. A study of hydrogen peroxide generation by, and antioxidant activity of, Granuflex™ (DuoDERM™) Hydrocolloid Granules and some other hydrogel/hydrocolloid wound management materials. *Br J Dermatol* 1993; 129 (2): 145-53
65. Postmes T, Vandeputte J. Recombinant growth factors or honey? *Burns* 1999; 25 (7): 676-8
66. Aristotle. *Historia animalium*. In: Smith JA, Ross WD, editors. *The works of Aristotle (350 BC)*. Vol IV. Oxford, UK: Oxford University, 1910
67. Molan PC, Allen KL. The effect of gamma-irradiation on the antibacterial activity of honey. *J Pharm Pharmacol* 1996; 48: 1206-9
68. Postmes T, van den Bogaard AE, Hazen M. The sterilization of honey with cobalt 60 gamma radiation: a study of honey spiked with *Clostridium botulinum* and *Bacillus subtilis*. *Experientia (Basel)* 1995; 51: 986-9

Correspondence and offprints: Associate Professor Peter C. Molan, Department of Biological Sciences, University of Waikato, Private Bag 3105, Hamilton, New Zealand.
E-mail: pmolan@waikato.ac.nz